

# Bezoar and bowel obstruction associated with the use of anti-gastro-oesophageal reflux medication in neonates

Gastro-oesophageal reflux is a common condition in neonates. A compound alginate preparation (CAP, Gaviscon) is often prescribed for this problem. This article reports on three cases of gastric bezoar and one case of bowel obstruction associated with its use. The authors propose CAP caused milk curd obstruction leading to serious consequences.

## Raj Singh Parmar<sup>1</sup>

MB BS, MD Paed, MRCPCH  
Paediatric Specialty Trainee  
rajparmar@doctors.org.uk

## Duncan Cameron<sup>2</sup>

MB ChB, MA, FRCPC  
Consultant Paediatrics

## P. N. Gopalakrishnan<sup>2</sup>

FRCPC  
Consultant Paediatrics

## Harriet J. Corbett<sup>1</sup>

MB ChB, MD, FRCS Paed  
Consultant Paediatric Surgeon

<sup>1</sup>Alder Hey Children's Hospital, Liverpool

<sup>2</sup>Glan Clwyd Hospital, Rhyl, Wales  
Institution where work undertaken:  
Neonatal Unit, Glan Clwyd Hospital

## Keywords

bezoar; Gaviscon; bowel obstruction; preterm birth; compound alginate preparation; anti-reflux medication

## Key points

**Parmar R.S., Cameron D., Gopalakrishnan P.N., Corbett H.J.** Bezoar and bowel obstruction associated with the use of anti-gastro-oesophageal reflux medication in neonates. *Infant* 2015; 11(3): 94-95.

1. 'Gavisconoma' is an overlooked condition.
2. Compound alginate preparation may cause bowel obstruction, which has not been previously reported.
3. There is a need for a cautious approach while prescribing anti-reflux medication in preterm infants.

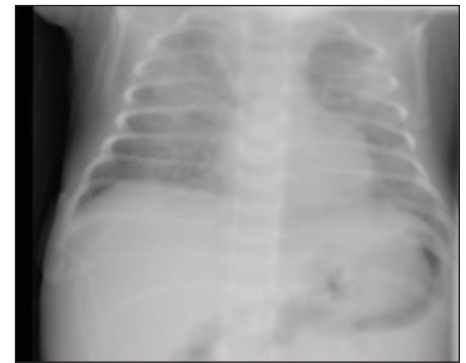
Gastro-oesophageal reflux (GOR) is the regurgitation of gastric contents into the oesophagus. It is particularly frequent in infants and is probably largely physiological, usually resolving spontaneously. The prevalence of GOR in infants is 20-40% higher than in children and adults.<sup>1</sup> It has been common practice to use Gaviscon, an alginate-containing antacid. This article reports on three cases of gastric bezoar (a pathological conglomeration of foreign material found in the gastrointestinal tract) and one case of bowel obstruction, highlighting potential complications associated with the use of Gaviscon in preterm infants.

The four preterm infants (of 25-32 weeks' gestation) were established on full enteral milk feeds between day 8-14. Gaviscon, a compound alginate preparation (CAP), was commenced on day 10-14 for symptoms of reflux. Bezoar was identified in three infants and resolved when stopping CAP. In the fourth case, the infant developed bowel obstruction requiring surgery and bowel resection. It is hypothesised that CAP caused milk curd obstruction in the fourth infant leading to serious consequences.

## Case reports

### Case 1

A male infant was born at 26<sup>+6</sup> weeks' gestation by normal vaginal delivery in good condition with a birth weight of 1kg. He needed artificial ventilation until day five of life, followed by continuous positive airway pressure (CPAP) for the next 24 hours. He required high flow oxygen until day 21 and then low flow oxygen. Enteral

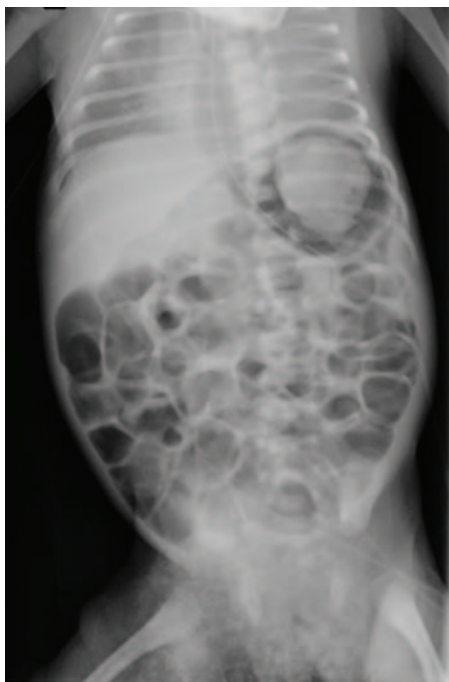


**FIGURE 1** Increased soft tissue density projected over the stomach region.

feeds were introduced at day four as expressed breast milk (EBM, 1mL every two hours). By day 11 he was fully enterally fed on EBM or donor breast milk (DBM) at 180mL/kg/day (ie 15mL every two hours). When on full feeds, desaturations (a decrease in oxygen concentration in the blood) were noticed during and after feeds. CAP, as Gaviscon infant powder mixed with feed, was introduced at day 12 for presumed GOR. In view of continued desaturations, a chest X-ray (**FIGURE 1**) was taken on day 13 that showed increased soft tissue density projected over the stomach region. Radiographic features were suggestive of Gaviscon bezoar and the Gaviscon was stopped. The infant continued to tolerate enteral feeds with fewer desaturations. On day 19, a repeat abdominal X-ray showed complete resolution of the dense opacity in the stomach.

### Case 2

A 1.19kg female infant was born at 28<sup>+3</sup> weeks' gestation by spontaneous vaginal



**FIGURE 2** A radiopaque mass in the stomach.

delivery in fair condition. The infant needed ventilatory support for three days and then CPAP for the next 24 hours. Subsequently she continued to breathe spontaneously in air. After a brief period on total parenteral nutrition (TPN), trophic feeds were built up gradually. Around day nine, she developed bradycardia and desaturations and needed CPAP. CAP, as Gaviscon, was added to her feed from day 10 onwards for presumed GOR. By day 14 she was fully enterally fed at a total feed volume of 180mL/kg/day of EBM with added Gaviscon. On day 16 she experienced sudden clinical deterioration with frequent apnoeic episodes requiring intubation and ventilation. An X-ray at that point showed a radiopaque mass in the stomach (**FIGURE 2**) with appearances of a bezoar. Gaviscon was omitted from feeds. Subsequent X-rays three days later showed complete resolution of the bezoar. Feeds were gradually increased once more and she was fully enterally fed again by day 20. Her subsequent course was unremarkable.

### Case 3

A 1.84kg male twin infant was born at 32 weeks' gestation by caesarean section in good condition. He required ventilation for one day followed by CPAP for two days. By day four he was breathing in air. Enteral

feeds were commenced on day two, building up to full enteral feeds by day eight. He was vomiting milk after feeds, which persisted despite reducing the total volume of feed to 150mL/kg/day. On Day 12, CAP as Gaviscon was added for suspected GOR. The following day the infant showed signs of sepsis and had a full septic screen. The chest X-ray showed a Gaviscon bezoar. Gaviscon was discontinued and the infant subsequently thrived.

### Case 4

A 540g female infant was born at 25<sup>+6</sup> weeks' gestation by emergency caesarean and required full ventilation. Enteral feeds were introduced on day five as 0.5mL DBM every two hours. The feeds were gradually increased to full feeds by day 14. Gaviscon was started on day 13 for suspected GOR. On day 15 the infant developed abdominal distension and vomiting. Feeds were stopped and she was treated as a possible case of necrotising enterocolitis (NEC). The infant continued to deteriorate and on day 18 she was transferred to the tertiary surgical unit. She underwent a laparotomy and resection of the necrotic jejunum with the formation of stomas. Operative findings were of milk curd NEC, with a dead perforated segment of jejunum full of milk curds and the rest of the small bowel full of semi-solid lumps of milk curd. There was massive contamination of the peritoneal cavity and a knotted mass of ischaemic bowel stuck to areas of healthy bowel. Approximately 25cm of proximal jejunum and 8m of distal bowel was left following resection. The infant made a good recovery post-surgery although developed complications secondary to prematurity, prolonged TPN and short gut syndrome.

### Discussion

Gaviscon bezoar ('Gavisconoma') was first reported in 1976<sup>2</sup> and since then, there has been a lack of case reporting in the medical literature. Most of the reported cases of gastric bezoars are lactobezoars (a conglomeration of milk and mucus in the stomach of milk-fed infants), which often cause gastric outlet obstruction, occasionally needing surgery.<sup>3</sup> To date, Gaviscon bezoars have not been reported as causing demonstrable harm and are

managed conservatively. Gastric bezoars can be diagnosed by radiography (plain or contrast) or abdominal ultrasound.

GOR is thought to be common in preterm infants but due to lack of evidence relating to its management in preterm infants, there is wide variation in diagnostic and treatment strategies. Common treatment strategies include non-drug options followed by drugs such as a CAP, which works by forming a 'raft' of jelly-like material in the stomach that may reduce reflux, although there is no evidence from randomised controlled trials to support or refute the use of CAP in preterm infants.<sup>4,5</sup> Indeed, the appearance of the bezoars might suggest that the CAP was doing its job correctly. In the first three cases, Gaviscon bezoar did not lead to serious complication and resolved on stopping Gaviscon. However, the introduction of Gaviscon in the fourth infant may well have triggered severe milk curd obstruction with the precipitated material found throughout the bowel. This led to the need to remove ischaemic bowel at surgery, indicating potential for very serious adverse effects. There are no previous reported cases of bowel obstruction associated with use of Gaviscon in preterm infants.

### Conclusion

Gaviscon is frequently used for the treatment of GOR in neonates although the evidence base for its use in preterm infants is limited. The authors advise caution in the use of Gaviscon in any preterm infant, particularly where there is no clear clinical evidence of GOR.

### References

1. Kennedy S. Update on drugs for gastro-oesophageal reflux disease. *Arch Dis Child Educ Pract Ed* 2007; 92:ep114-18.
2. Hewitt G.J., Benham E.S. A complication of Gaviscon in a neonate – 'the Gavisconoma'. *Aust Paediatr J* 1976;12:47-48.
3. Heinz-Erian P, Gassner I, Klein-Franke A. et al. Gastric lactobezoar – a rare disorder? *Orphanet J Rare Dis* 2012;7:3.
4. Huang R.C., Forbes D.A., Davies M.W. Feed thickener for newborn infants with gastro-oesophageal reflux. *Cochrane Database Syst Rev* 2002: CD003211.
5. Del Buono R., Wenzl T.G., Ball G. et al. Effect of Gaviscon Infant on gastro-oesophageal reflux in infants assessed by combined intraluminal impedance/pH. *Arch Dis Child* 2005;90:460-63.