

# Necrotising enterocolitis – a cause for neonatal perforated appendicitis

A report of an 11 day old full term neonate with a perforated appendix caused by necrotizing enterocolitis is presented with a discussion of the current literature. Appendicitis and NEC remain rare entities in term neonates. However in the term baby presenting with signs suggestive of NEC, the possibility of appendicitis requiring laparotomy must be considered.

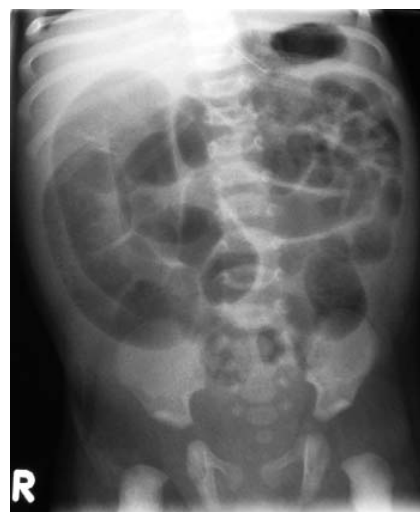## CASE REPORT

A full term baby girl born by spontaneous vaginal delivery presented on day 3 of life to her local hospital with blood stained stools, lethargy, off feeds and pyrexia. She was unwell with poor peripheral perfusion and required fluid resuscitation. She had no respiratory distress. On abdominal examination mild discomfort was noted in the right iliac fossa. Abdominal radiograph was unremarkable and her acid-base balance was normal. She was commenced on intravenous cefotaxime, gentamicin and metronidazole, kept nil by mouth and commenced total parenteral nutrition (TPN). Blood cultures were positive for *E.coli* and *Staphylococcus aureus* and stools were positive for adenovirus.

On day 9 of life she developed abdominal distension without guarding. Repeat abdominal radiograph showed mildly dilated bowel with no intramural changes and no pneumoperitoneum (**FIGURE 1**). Antibiotics were changed to teicoplanin, gentamicin and metronidazole and she was transferred to the paediatric surgery (tertiary referral) centre.

She was afebrile and haemodynamically stable following transfer. Her initial C Reactive Protein (CRP) was 217 on day 3 of life, but had normalised by day 9. On day 10 of life she developed increased abdominal distention and bile stained aspirates. Further abdominal radiograph showed grossly dilated bowel loops with no intramural gas or pneumoperitoneum. Due to clinical signs of bowel obstruction she proceeded to laparotomy.

Intraoperative findings were of a necrotic disintegrated appendix with no macroscopically identifiable appendix



**FIGURE 1**  
Abdominal radiograph demonstrating dilated loops of bowel with no evidence of pneumoperitoneum.

**Emma Stormer** MBCHB, MRCS, Paediatric Surgery Trainee  
emma.stormer@doctors.org.uk

**Steve Gould** FRCPath, Consultant Paediatric Pathologist

**Kaye Platt** MBCHB, FRCR, Consultant Paediatric Radiologist

**Kokila Lakhoo** PhD, FRCS, FCS(SA), MRCPCH, MBCHB,  
Consultant Paediatric Surgeon

Depts of Paediatric Surgery and Pathology, John Radcliffe Hospital, Oxford.

Emma Stormer is currently working in the Dept of Paediatric Surgery, Royal Hospital for Sick Children, Yorkhill, Glasgow.

tissue. There was a large hole in the caecum at the level of the appendix stump. She underwent an ileo-caecal resection and primary ileo-right colic anastomosis. She made an uneventful post operative recovery and was tolerating full feeds by day 6.

## Pathology

The caecal perforation was confirmed with a residual part of the distal appendix adherent to the ileal wall. Histologically, there was full thickness necrosis proximally with mucosal replacement by granulation tissue in the residual distal tip (**FIGURE 2**). The caecum showed a patchy mucosal ulceration with epithelial regeneration. At the distal colonic resection margin, there was a normal muscle coat, submucosal fibrosis and a simplified, regenerating mucosa with residual ulceration. The lumen was narrowed.

## Discussion

Necrotising enterocolitis (NEC) is thought of primarily as a disease of prematurity, however NEC in term neonates accounts for about 10% of cases<sup>1</sup>. In the term neonate the predisposing factors to NEC such as birth asphyxia, hypoglycaemia, polycythaemia, respiratory distress, intrauterine growth retardation (IUGR), congenital heart disease, gastroschisis, sepsis, umbilical lines, and premature rupture of membranes, are often not present<sup>1,2</sup>. It has been suggested that the time of presentation and site of NEC differ in the term population. In the preterm population NEC usually presents between days 7 to 14<sup>3,4</sup>.

In term neonates NEC tends to be of earlier onset than the preterm neonate. Andrews et al<sup>2</sup> found the majority of term neonates presented within the first 48 hours of life, Wiswell et al<sup>3</sup> showed an age of onset at about 2 days and Maayan-Metzger et al<sup>1</sup> found a mean age of onset of 4.1 days. Both

also suggested that colonic disease rather than ileal was more prevalent in the term group. This implies that NEC in term neonates may be of a different pathogenesis with the same or similar clinical end point. This case shows many of these features. The colonic and caecal injury in this case is very typical of 'recovering' NEC. At the distal resection margin, the presence of typical mucosal features in the absence of any serosal or muscularis propria changes, suggests the pathology here is more than secondary to an appendiceal mass. It is therefore likely the appendiceal involvement and 'appendicitis' was secondary to preceding NEC.

Appendicitis in neonates remains a rare entity. Other reported aetiologies include Hirschsprung's disease, cystic fibrosis and meconium plug<sup>5</sup>. Our case showed no evidence of these conditions. Less common aetiologies include incarcerated inguinal hernia<sup>6,7</sup>, umbilical hernia, group B streptococci<sup>8</sup> and *Pseudomonas aeruginosa*<sup>9</sup> septicaemia and chorioamnionitis<sup>10</sup>.

Although appendicitis is rare in neonates it does carry a high perforation rate<sup>11,12</sup>. This could be related to either the underlying cause of the appendicitis – eg Hirschsprung's disease or cystic fibrosis – or bowel ischaemia. Historically the diagnosis of abdominal appendicitis in the neonate was found at autopsy in 57% of cases, with a mortality rate of about 80% up until the 1970s<sup>12-14</sup>. The first neonate to survive laparotomy for abdominal appendicitis was reported by Meigher et al in 1952<sup>15</sup>. However in 1908 Lillenthal reported a survivor with appendicitis within a scrotal hernia<sup>16</sup>. In 1970 the mortality rate for reported cases of perforated appendicitis in the neonate was 95%<sup>14</sup>.

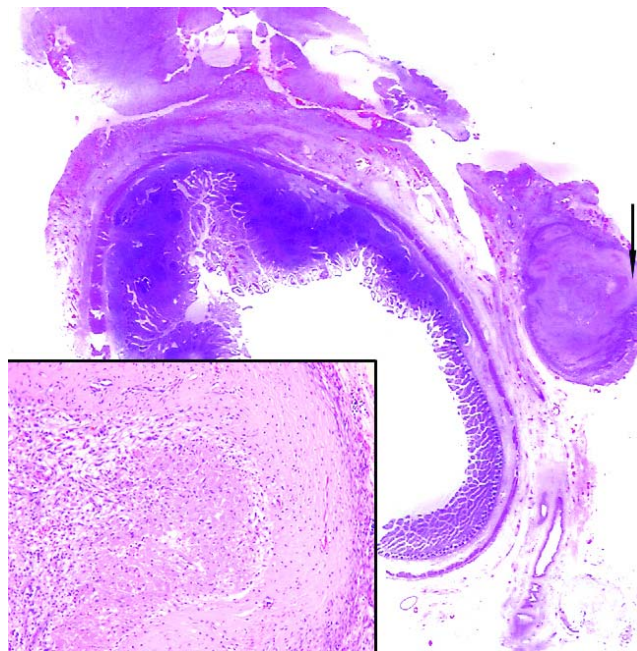
Interestingly of the 141 cases of neonatal appendicitis reported in the English language literature from 1901-2000, almost half (48%) were full term neonates<sup>12</sup>. The perforation rate over that time period was consistent at approximately 70-80%, but with associated decrease in mortality which had dropped to 28% between 1985-2000<sup>12</sup>.

Neonatal appendicitis has not been reported on autopsy in the last 25 years<sup>12</sup>. The diagnosis of appendicitis is now usually made intraoperatively, when laparotomy is performed for perforation or NEC not responding to medical management. This means that the diagnosis is frequently delayed. Neonates do not have the same omental protection as older children and adults, and therefore cannot localise infection to an appendix abscess, but instead there tends to be generalised contamination<sup>17</sup>. The small proportions of the neonatal abdomen also contribute. In addition the neonatal appendix is thin walled with a delicate blood supply on a long mesentery which therefore lends itself to perforation<sup>14,18</sup>.

Term neonates have greater physiological reserve than preterm neonates and therefore may not exhibit haemodynamic and clinical instability in response to worsening NEC (or appendicitis). Therefore a low threshold for surgery in these instances has been recommended<sup>2</sup>. This viewpoint would be supported by a fatal case of necrotising fasciitis following acute appendicitis in a term neonate<sup>19</sup>.

## References

1. Maayan-Metzger A., Itzchak A., Mazkereth R., Kuint J. Necrotizing enterocolitis in full term infants: Case-control study and review of the literature. *J Perinatol* 2004; **24**(8): 494-99.



**FIGURE 2** Low power view of ileum with part of the appendiceal tip adherent to the serosal surface. Superiorly, some residual proximal appendiceal wall can be seen close to the ileal wall. The insert (from the arrowed part of the appendiceal wall) shows granulation tissue and necrotic material replacing mucosa together with submucosal fibrosis and muscularis thinning.

- Andrews D.A., Sawin R.S., Ledbetter D.J., Schaller. Necrotizing enterocolitis in term neonates. *Am J Surg* 1990; **159**(5): 507-09.
- Wiswell Te., Robertson C.F., Jones T.A., Tuttle D.J. Necrotizing enterocolitis in full-term infants. *Am J Dis Child* 1988; **142**: 532-35.
- Thilo E.H., Lazarte R.A., Hernandez J.A. Necrotizing enterocolitis in the first 24 hours of life. *Pediatrics* 1973; **73**: 476-80.
- Van Veenendaal M., Plotz F.B., Nikkels P.G.J., Bax N.M.A. Further evidence for an ischemic origin of perforation of the appendix in the neonatal period. *J Pediatric Surgery* 2004; **39**(8): E11-12.
- Martins J.L., Peterlini F.L., Martins E.C. Neonatal acute appendicitis: A strangulated appendix in an incarcerated inguinal hernia. *Pediatr Surg Int* 2001; **17**(8): 644-45.
- Iuchtman M., Kirshon M., Feldman M. Neonatal pyosclerum and perforated appendicitis. *J Perinatol* 1999; **19**(7): 536-37.
- Managoli S., Chaturvedi P., Vilhekar K.Y., Gupta D., Ghosh S. Perforated acute appendicitis in a term neonate. *Indian J Pediatr* 2004; **71**(4): 357-58.
- Lin Y.L., Lee C.H. Appendicitis in infancy. *Pediatr Surg Int* 2003; **19**(1-2): 1-3.
- Pressman A., Kwar B., Abend M. et al. Acute perforated neonatal appendicitis associated with chorioamnionitis. *Eur J Pediatr Surg* 2001; **11**: 204-06.
- Stiefel D., Stallmach T., Sacher P. Acute appendicitis in neonates: Complication or morbus sui generis. *Pediatr Surg Int* 1998; **14**: 122-23.
- Karaman A., Cavusoglu Y.H., Karaman I., Cakmak O. Seven cases of neonatal appendicitis with a review of the English language literature of the last century. *Pediatr Surg Int* 2003; **19**(11): 707-9. Epub.
- Srouji M., Buck B.E. Neonatal appendicitis: Ischemic infarction in incarcerated inguinal hernia. *J Pediatr Surg* 1978; **13**: 177-79.
- Parson J.M., Miscall B.G., McSherry C.K. Appendicitis in the newborn infant. *Surgery* 1970; **67**: 84.
- Meigher S.C., Lucas A.W. Appendicitis in the newborn: Case Report. *Ann Surg* 1953; **136**: 1044.
- Schorlemmer G.R., Herbst C.A. Perforated neonatal appendicitis. *South Med J* 1983; **76**: 536-37.
- Massad M., Srouji M., Awdeh A., et al. Neonatal appendicitis: Case report and revised review of the English literature. *Z Kinderchir* 1986; **41**: 241-43.
- Walker R.H. Appendicitis in the newborn infant. *J Pediatr* 1958; **51**: 429-34.
- Lodha A., Wales P.W., James A. et al. Acute appendicitis with fulminant necrotizing fasciitis in a neonate. *J Pediatr Surg* 2003; **38**(11): E5-6.